

# Journal of Biomedical Optics

BiomedicalOptics.SPIEDigitalLibrary.org

## **Photobiomodulation reduces oral mucositis by modulating NF- $\kappa$ B**

Marina Curra  
Ana Carolina Amorim Pellicoli  
Nélson Alexandre Kretzmann Filho  
Gustavo Ochs  
Úrsula Matte  
Manoel Sant'Ana Filho  
Marco Antonio Trevizani Martins  
Manoela Domingues Martins

# Photobiomodulation reduces oral mucositis by modulating NF- $\kappa$ B

Marina Curra,<sup>a</sup> Ana Carolina Amorim Pellicoli,<sup>a</sup> Néilson Alexandre Kretzmann Filho,<sup>b</sup> Gustavo Ochs,<sup>b</sup> Úrsula Matte,<sup>b</sup> Manoel Sant'Ana Filho,<sup>a</sup> Marco Antonio Trevizani Martins,<sup>a</sup> and Manoela Domingues Martins<sup>a,\*</sup>

<sup>a</sup>Universidade Federal do Rio Grande do Sul, School of Dentistry, Department of Oral Pathology, Rua Ramiro Barcelos, 2492, Porto Alegre, Rio Grande do Sul 90035-003, Brazil

<sup>b</sup>Hospital de Clínicas de Porto Alegre, Department of Gene Therapy, Rua Ramiro Barcelos, 2350, Porto Alegre, Rio Grande do Sul 90950-000, Brazil

**Abstract.** The aim of this study was to evaluate NF- $\kappa$ B during 5-fluorouracil (FU)-induced oral mucositis and ascertain whether photobiomodulation (PBM), as a preventive and/or therapeutic modality, influences this transcription factor. Ninety-six male golden Syrian hamsters were allocated into four groups: control (no treatment); PBM therapeutic, PBM preventive, and PBM combined. Animals received an injection of 5-FU on days 0 and 2. On days 3 and 4, the buccal mucosa was scratched. Irradiation was carried out using a 660-nm, 40-mW diode laser at 6 J/cm<sup>2</sup> during 6 s/point, 0.24 J/point, for a total dose of 1.44 J/day of application. Animals were euthanized on days 0, 5, 10, and 15 ( $n = 6$ ). Buccal mucosa was removed for protein quantification by Western blot. Clinical analysis revealed that PBM groups exhibited less mucositis than controls on day 10. Control animals exhibited lower levels of NF- $\kappa$ B during mucositis development and healing. The preventive and combined protocols were associated with higher NF- $\kappa$ B levels at day 5; however, the therapeutic group had higher levels at days 10 and 15. These findings suggest that the preventive and/or therapeutic PBM protocols reduced the severity of oral mucositis by activating the NF- $\kappa$ B pathway. © 2015 Society of Photo-Optical Instrumentation Engineers (SPIE) [DOI: 10.1117/1.JBO.20.12.125008]

Keywords: laser therapy; mucositis; NF- $\kappa$ B; low-level laser.

Paper 150517RR received Aug. 6, 2015; accepted for publication Nov. 20, 2015; published online Dec. 29, 2015.

## 1 Introduction

Oral mucositis is a major side effect of chemoradiotherapy and radiotherapy, particularly in patients with head and neck cancer. The clinical manifestations of oral mucositis include erythematous, erosive, and/or ulcerative lesions, and mild-to-severe pain.<sup>1</sup> Mucositis can lead to significant impairment of quality of life, prolong hospital stays, increase readmission rates, compromise the patient's nutritional status, and even lead to discontinuation of cancer therapy and, occasionally, death.<sup>2,3</sup> The exact mechanisms whereby cytotoxic chemotherapy drugs and radiotherapy cause mucositis have not been fully elucidated. However, this condition seems to result from a series of dynamic interactions among molecular and cellular events involving all elements of the mucosa (epithelium and connective tissue).<sup>4</sup>

The pathobiology of oral mucositis has been described as a five-phase process: initiation, message generation, signaling and amplification, ulceration, and healing.<sup>2</sup> Initiation occurs after administration of chemotherapy or radiotherapy, which promotes DNA and non-DNA damage and the generation of reactive oxygen species (ROS). The second phase is the message generation, which involves the upregulation of transcription factors, including NF- $\kappa$ B and STAT3, and the activation of several cytokines. The signaling and amplification phase represents the production of several proteins, such as tumor necrosis factor, interleukin-1 $\beta$ , and interleukin-6, which cause direct tissue damage and provide positive feedback to amplify the process. The tissue alterations result in loss of epithelium, which produces painful lesions, bacterial infiltration, and an influx of macrophages

and other inflammatory cells, characterizing the ulceration phase. After the cessation of stimuli (chemotherapy or radiotherapy), the healing process can be established.<sup>2,4</sup>

Some studies have shown that the activation of NF- $\kappa$ B and subsequent upregulation of proinflammatory cytokines may be a potentially important factor in the pathobiology of mucositis.<sup>5,6</sup> These studies found that the changes in serum levels of NF- $\kappa$ B preceded the clinical appearance of oral mucositis. An evolving understanding of the mechanisms involved in the pathobiology of mucositis has contributed to the development of strategies for the prevention and treatment of this condition during cancer therapy.<sup>5,6</sup>

In 2014, the Mucositis Study Group of the Multinational Association of Supportive Care in Cancer and International Society of Oral Oncology (MASCC/ISOO)<sup>7</sup> published clinical practice guidelines for management of mucositis secondary to cancer therapy. The panel recommends the following protocols: (1) 30 min of oral cryotherapy to be used to prevent oral mucositis in patients receiving bolus 5-FU chemotherapy; (2) recombinant human keratinocyte growth factor-1 (KGF-1/palifermin) to be used to prevent oral mucositis in patients receiving high-dose chemotherapy and total body irradiation, followed by autologous stem cell transplantation, for a hematological malignancy; (3) benzydamine mouthwash to be used to prevent oral mucositis in patients with head and neck cancer receiving moderate-dose radiation therapy (up to 50 Gy), without concomitant chemotherapy; and (4) photobiomodulation (PBM) (wavelength at 650 nm, power of 40 mW, and each square centimeter treated with the required time to a tissue energy dose of 2 J/cm<sup>2</sup>), to be used to prevent oral mucositis

\*Address all correspondence to: Manoela Domingues Martins, E-mail: manomartins@gmail.com

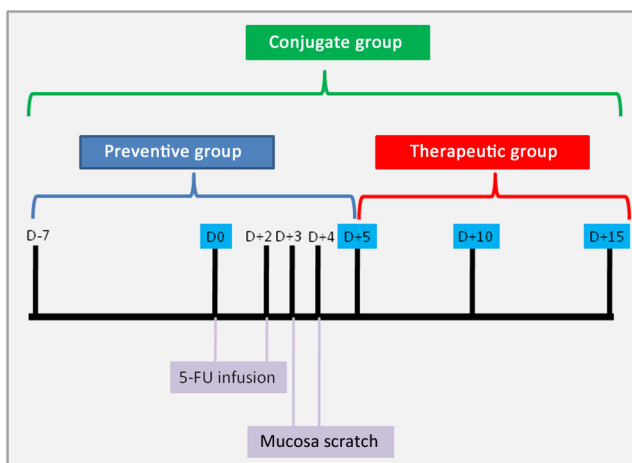
in patients receiving hematopoietic stem cell transplantation conditioned with high-dose chemotherapy, with or without total body irradiation. The inclusion of PBM in current oral mucositis guideline is based on several clinical evidences supporting the use for prevention and treatment of oral mucositis.<sup>8,9</sup> PBM has been proposed to exert antiinflammatory effects and control mucositis-associated pain.<sup>10,11</sup> Furthermore, PBM improves cell proliferation and migration and transcription of genes involved in wound healing.<sup>12–16</sup> The use of PBM is safe without side effects. Negative aspects for this therapy include the cost of laser equipment and the labor-intensiveness of this modality (because many regimens involve the daily treatment of patients). Few studies analyzed the cellular and molecular aspects of PBM in the pathobiology of oral mucositis.<sup>6,17</sup> In previous analyses<sup>8,18</sup> using an animal model, a positive effect of PBM was observed both in clinical and histopathological examinations compared with corticosteroid<sup>8</sup> and cryotherapy.<sup>18</sup> In general, both studies showed that PBM groups exhibited lower inflammatory reaction and better epithelium aspects deprived of bleeding, ulcers, and abscesses.

The objectives of the present study were to evaluate tissue levels of activated NF-kB during the development of oral mucositis and determine whether preventive and/or therapeutic PBM influences this transcription factor in a hamster model of 5-fluorouracil (FU)-induced oral mucositis.

## 2 Methods

### 2.1 Animal Model

All experiments were carried out in accordance with the US National Academy of Sciences Guide for the Care and Use of Laboratory Animals and received approval from the ethics committee of Hospital de Clínicas de Porto Alegre, Brazil, under process number 11-0134. Ninety-six male golden Syrian hamsters (age 8 weeks, body mass ~150 g) were kept under standard conditions of temperature (20°C to 24°C) and light/dark cycle and given access to solid food and water *ad libitum*. The animals were randomly divided into four cohorts of 24 each: control (no treatment), therapeutic (PBM from D+5 to D+15), preventive (PBM from 7 days before [D-7] 5-FU induction until day 5 [D+5]), and combined (PBM from D-7 to D+15) (Fig. 1).



**Fig. 1** Diagram of experimental protocol adopted in this study.

### 2.2 Oral Mucositis Induction

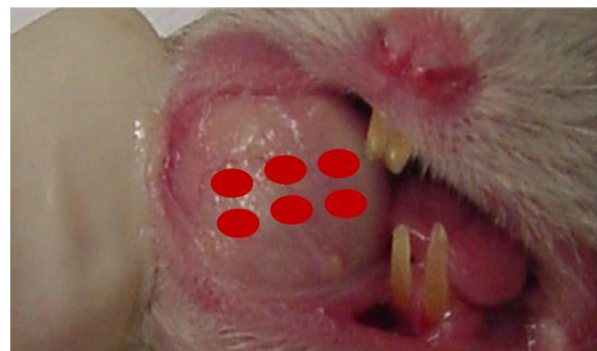On day 0 (D0), a 60-mg/kg dose of 5-FU was administered intraperitoneally to each animal, and on day 2 (D+2), 40 mg/kg of the same drug was infused, following the same protocol used in previous studies.<sup>8,19</sup> On days 3 (D+3) and 4 (D+4), the right buccal mucosa of each animal was scratched twice with the tip of a sterile needle, always by the same operator. Six animals from each group were euthanized using a CO<sub>2</sub> chamber on D0, D+5, D+10, and D+15. The right buccal mucosa was photographed, resected, flash-frozen in liquid nitrogen for 1 h, and stored at -80°C.

### 2.3 Photobiomodulation

PBM was applied by a single professional using a continuous-wave indium gallium aluminum phosphide (InGaAlP) diode laser (MM Optics, São Carlos, SP, Brazil) with a wavelength of 660 nm (visible-red). The irradiation was done in the middle of the right buccal mucosa in six points (Fig. 2) in spot and contact mode techniques. The irradiation parameters were as follows: spot size 0.04 cm<sup>2</sup>, power output 40 mW, irradiance 1 W/cm<sup>2</sup>, duration 6 s, and energy density 6 J/cm<sup>2</sup>. The dose was 0.24 J/point, for a total of 1.44 J/day of application. PBM was applied daily during the period established for each group (Fig. 1). The control group was treated under identical conditions, but with the laser device switched off. The output power of the equipment was checked using a power meter (Laser Check; MMOptics LTDA, São Paulo, Brazil).

### 2.4 Clinical Analysis

Oral mucositis severity score was calculated from visual evaluation of photos obtained in D0, D+5, D+10, and D+15. Inflammatory aspects such as erythema, hyperemia, bleeding, epithelial ulcers, and abscesses were assessed by a blind evaluator and scored from 0 to 3 based on the method described by Lima et al.<sup>20</sup> as follows: 0—normal buccal mucosa, with absence of or slight erythema and hyperemia, and no areas of bleeding, ulceration, or abscesses; 1—moderate erythema and hyperemia, with no areas of bleeding, ulceration, or abscesses; 2—severe erythema and hyperemia, presence of areas of bleeding, small ulcers, or eschars, but no abscesses; and 3—severe erythema and hyperemia, presence of areas of bleeding, extensive ulcers, and abscesses.



**Fig. 2** Laser irradiation procedure. Red dots represent the points of laser delivery.

## 2.5 NF-kB Analysis

The frozen right buccal mucosa was removed from  $-80^{\circ}\text{C}$  and maintained in ice to avoid protein denaturation. The protein extraction was performed using glycerol phosphate buffer containing hypotonic solution with NP-40 to separate cytoplasmic cell fractions and glycerol-saline buffer to separate the nucleus cell fraction. The mixture was incubated for 30 min at  $4^{\circ}\text{C}$  and centrifuged for 30 min at  $13,000 \times g$  at  $4^{\circ}\text{C}$ . The protein concentration was measured by the Bradford assay. A  $15\text{-}\mu\text{g}$  aliquot of nuclear extract was separated with 10% sodium dodecyl sulfate-polyacrylamide gel electrophoresis and transferred onto polyvinylidene difluoride membranes (Millipore). The membranes were blocked with 5% milk tris-buffered saline between, then incubated with primary anti-NF-kB (1:1000; Cell Signaling Technology) antibody overnight at  $4^{\circ}\text{C}$ , p65 protein (65 kDa). The membranes were then washed, blocked with 5% milk, and incubated with goat anti-rabbit secondary antibodies (1:5000; Cell Signaling Technology) for 1 h at room temperature. The proteins were detected by an enhanced chemiluminescence detection system (ECL kit, Millipore). The density of the specific bands was quantified with an imaging densitometer (ImageJ).  $\beta$ -actin was used as the relative control. For semiquantitative analysis, arbitrary values were calculated as the product of area  $\times$  intensity of bands. The resulting number for NF-kB bands was divided by the resulting number for  $\beta$ -actin.

## 2.6 Statistical Analysis

Clinical data were expressed as means and standard deviations. All statistical analyses were carried out in GraphPad Prism 6. Groups, evaluation times, and the interaction between group and evaluation time were compared using the one-way analysis of variance (ANOVA) multiple comparisons test followed by Tukey's post-hoc correction, when necessary. The significance level was set at 5% ( $p < 0.05$ ).

## 3 Results

### 3.1 Photobiomodulation Promotes Accelerated Wound Healing

Clinical studies have demonstrated the benefits of PBM in wound healing and in the treatment of several inflammatory conditions.<sup>3,13–15,21–23</sup> Our results showed a gradual increase in clinical scores of control animals from D0 to D+10, when the peak severity of oral mucositis was observed, represented by severe erythema and hyperemia, hemorrhagic areas, and extensive ulceration and/or abscess formation (score 3). At this time (D+10), all PBM groups exhibited lower mean scores (score 1). On D+15, all groups exhibited low oral mucositis scores. Figure 3 demonstrates the mean clinical scores of each group during the experimental periods. The control group differed from all PBM groups on days 10 ( $p < 0.003$ ) and 15 ( $p = 0.042$ ). No significant difference was observed among the different PBM protocols ( $p > 0.05$ ).

### 3.2 Photobiomodulation Activates NF-kB During Development of Oral Mucositis

In the nucleus, NF-kB dimers bind to a kappa B site in the promoter or enhancer region of target genes, thereby controlling expression of genes involved in inflammatory responses. NF-kB activation can induce the transcription of many genes

such as cytokines, growth factors, adhesion molecules, and mitochondrial antiapoptotic genes.<sup>1–5</sup> In the present study, levels of activated NF-kB were analyzed by the appearance of bands and by relative band density compared with the loading in each lane ( $\beta$ -actin).

Comparison of NF-kB levels among groups according to the experimental period showed that, on day 5, the combined and preventive groups exhibited higher NF-kB levels than the control and therapy groups ( $p < 0.05$ ). On day 10, animals in the therapeutic group expressed the highest levels of NF-kB compared with the other groups ( $p < 0.05$ ). Finally, on day 15, all groups showed a reduction in NF-kB level, but the therapeutic group exhibited higher levels than the control, combined, and preventive groups ( $p < 0.05$ ) (Fig. 4).

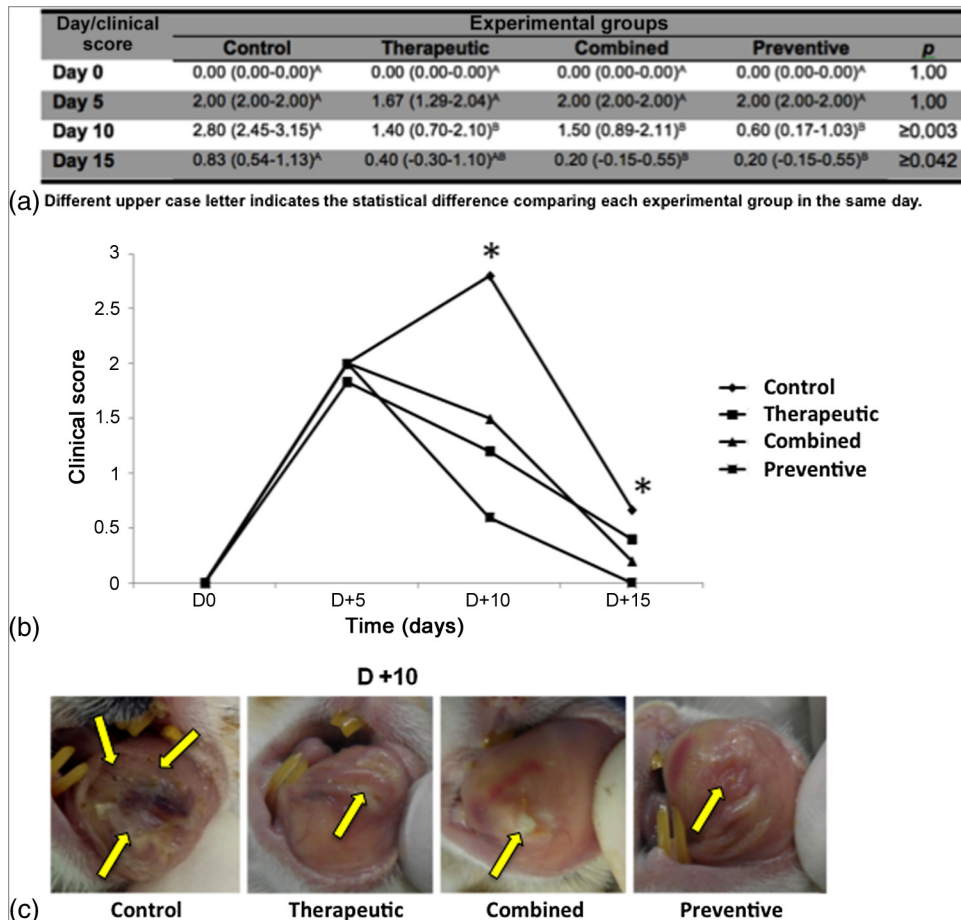
Analysis of NF-kB levels within each group throughout the experimental period revealed that the control and therapeutic groups, as well as the preventive and combined groups, exhibited the same patterns of protein expression. In the control and therapeutic groups, the NF-kB level increased from days 5 to 10 ( $p < 0.05$ ), at which time it peaked, then it subsequently decreased from days 10 to 15 ( $p < 0.05$ ). In the preventive and conjugated groups, the NF-kB level gradually decreased from days 5 to 15 ( $p < 0.05$ ) (Fig. 5).

## 4 Discussion

Oral mucositis is a major side effect of cancer treatment modalities including chemotherapy and head and neck radiotherapy. Its pathobiology involves the activation of NF-kB and subsequent upregulation of proinflammatory cytokines, resulting in tissue damage and clinical manifestations of inflammatory reaction, followed by the healing process.<sup>2,9</sup> Among the therapeutic options available for oral mucositis, PBM seems to have positive effects, especially in terms of reducing pain and preventing inflammatory lesions.<sup>7,11–16</sup> The mechanisms by which PBM influences oral mucositis are still unknown, as is its role on NF-kB modulation. In this study, we analyzed NF-kB levels during the development of oral mucositis in hamsters under PBM treatment. Our results showed that, clinically, PBM was able to reduce the severity of oral mucositis; biologically, this was achieved by activation of the NF-kB pathway.

The animal model used in this study followed the protocol of 5-FU-induced mucositis developed by Sonis et al.<sup>24</sup> and modified by Leitao et al.<sup>25</sup> This is a useful model to study the five overlapping phases of oral mucositis pathobiology: initiation, upregulation and message generation, signaling and amplification, ulceration, and healing.<sup>1,2,4</sup> It is also helpful for the assessment of molecular and cellular aspects after different PBM protocols. NF-kB and several cytokines have been suggested to play key roles in mucositis development. Changes in NF-kB levels have been demonstrated in alimentary tract mucositis caused by different chemotherapeutic agents.<sup>5,6</sup> It is also well recognized that NF-kB modifications occur prior to clinical evidence of mucositis occurrence. Such findings have led to a better understanding of the pathobiology of mucositis and have assisted in the search for more effective therapies for this complication of cancer treatment.<sup>26</sup>

Our clinical results showed that the mucositis severity peaked on D+10 in controls, indicating the effectiveness of the experimental model, as described by Sonis et al.<sup>24</sup> All PBM groups, regardless of application protocol, exhibited a reduction in oral mucositis, as demonstrated by significantly lower severity scores in PBM animals as compared with control



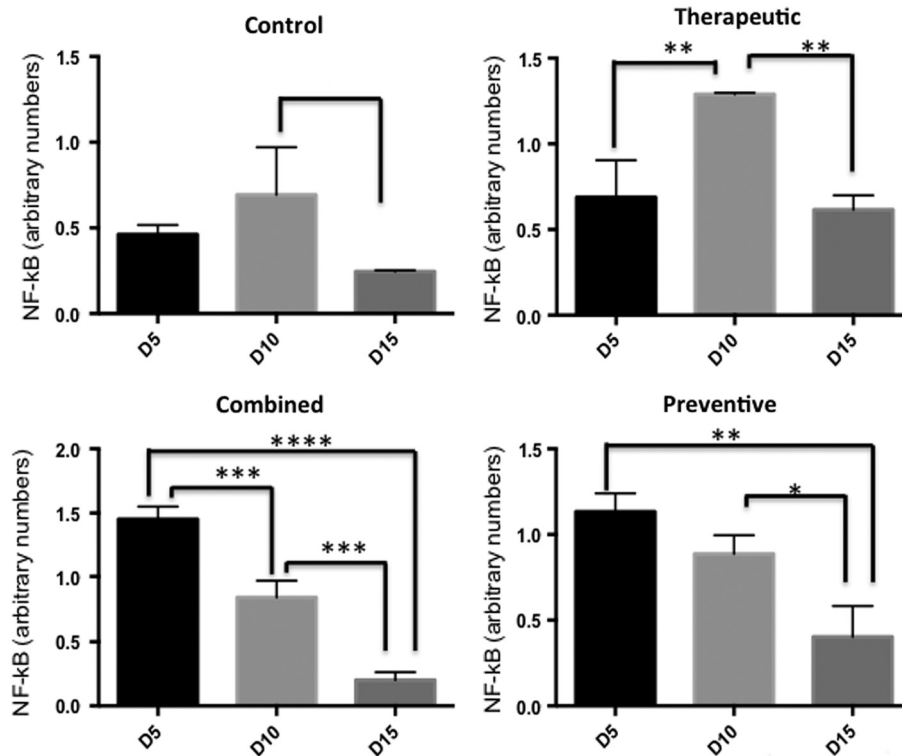
**Fig. 3** Clinical analysis: (a) table demonstrating the mucositis score according to the experimental time and group. Observe that on days 10 and 15, control group presented higher score compared with all photobiomodulation (PBM) groups; (b) graphic illustrating that PBM induces significant reduction in clinical oral mucositis on days 10 and 15 compared with control group. Asterisks denote the statistical significance ( $*p < 0.05$ ); and (c) clinical aspect of hamster buccal mucosa at D+10 in the control, therapeutic, combined, and preventive groups. Note that the control group exhibited an extensive ulceration. Arrows indicate the area with oral mucositis.

on D+10. Despite the positive effects observed in all PBM groups, greater efficiency in lesion repair at D+15 was observed in the preventive and combined groups. Studies in animals<sup>18</sup> and in humans<sup>11</sup> have demonstrated the effectiveness of PBM in reducing the level and severity of mucositis, especially when administered as a preventive modality. Based on the scientific evidence, the MASCC/ISOO group<sup>7</sup> suggested that PBM has the potential to become routine practice in the prevention of oral mucositis and could reduce the pain associated with this condition.

PBM has been widely used in inflammatory conditions. Its main effects are to accelerate wound healing through modulation of the inflammatory process, as well as exert analgesic and biomodulatory effects.<sup>15</sup> Such effects may be related to the action of PBM in preventing cell death<sup>15,27,28</sup> and restoring cellular metabolism.<sup>15,19,29</sup> Within this context, our study hypothesizes that the clinical benefits of PBM are likely associated with NF-kB modulation. NF-kB is a dimeric transcription factor formed by members of a family of proteins that share a conserved N-terminal dimerization/DNA-binding region known as the Rel homology domain.<sup>30</sup> Oxidative stress and inflammatory stimuli activate I $\kappa$ B kinase (IKK), which in turn phosphorylates

I $\kappa$ B, causing the release of NF-kB dimers and their nuclear translocation. In the nucleus, NF-kB dimers bind to a kappa B site in the promoter or enhancer region of target genes, thereby controlling the expression of several genes involved in the inflammatory response. Once activated, NF-kB can induce the transcription of many genes which encode molecules such as cytokines, growth factors, adhesion molecules, and mitochondrial antiapoptotic proteins. The NF-kB gene plays a particularly crucial role in the immune response. Several studies have shown that it is a key mediator in inflammation, as well as in tumor development, progression, and neovascularization.<sup>30-32</sup>

Our results showed that on day 5 after 5-FU infusion (D+5), similar levels of activated NF-kB were detected in the control and PBM groups. This is consistent with our clinical observations demonstrating that all groups were at the same stage of mucositis induction. The experimental model consisted of mucosal injury (scratching) on D+3 and D+4 to induce mucositis. Therefore, independent of group allocation, all animals experienced a traumatic and chemical ulceration, and similar tissue reactions were expected on D+5. By D+10, controls had developed a severe mucositis, which is consistent with the



**Fig. 4** Western blot analysis of NF-kB protein levels between groups by experimental time. On day 5, animals in the combined and preventive groups exhibited higher NF-kB levels than the control and therapeutic groups. On day 10, levels of NF-kB were highest in the therapeutic group. On day 15, all groups exhibited reductions in NF-kB level. The therapeutic group exhibited higher NF-kB levels than the control, combined, and preventive groups. Asterisks denote the statistical significance (\* $p < 0.05$ , \*\* $p < 0.01$ , \*\*\* $p < 0.001$ , and ns  $p > 0.05$ ).

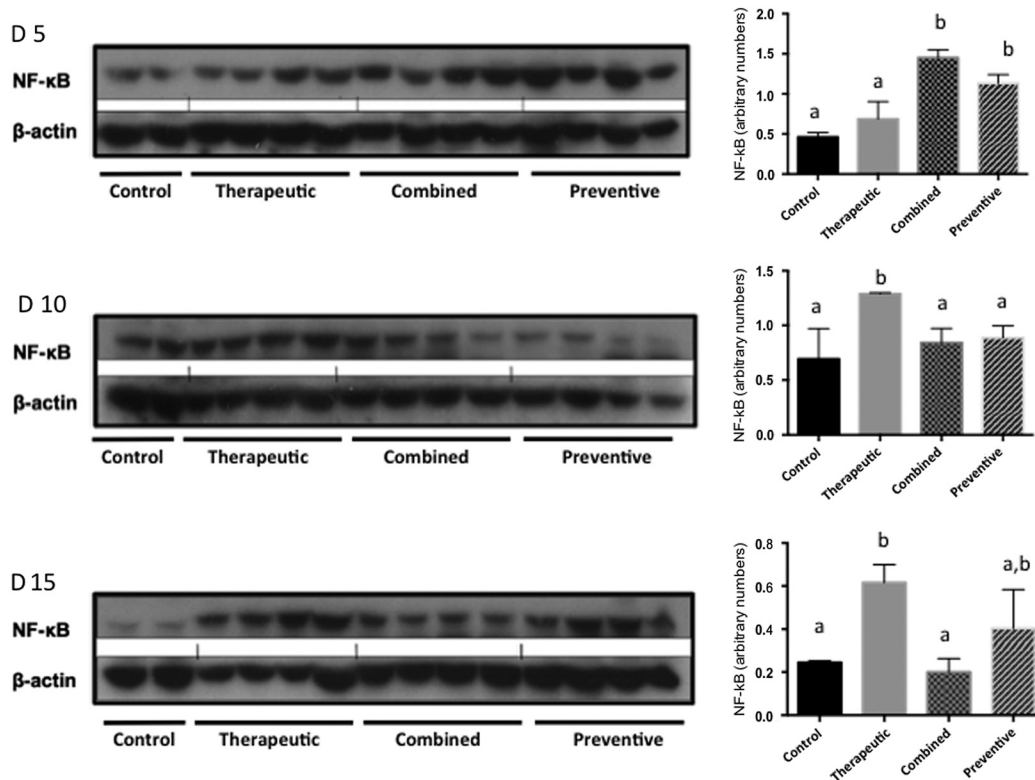
findings of Sonis,<sup>2</sup> whereas the PBM groups had lower severity scores. At this time point, animals in the PBM groups showed higher levels of activated NF-kB protein than controls. This result was surprising, because high levels of NF-kB have been associated with severity of several inflammatory diseases.<sup>30,31</sup> However, Logan et al.<sup>5,6</sup> studied the tissue expression of NF-kB and other proinflammatory cytokines in oral and intestinal mucositis induced by irinotecan, 5-FU, and methotrexate and reported that the type of drug administered influences the level of this protein. The authors reported that the mucositis induced by 5-FU was not associated with a significant increase in tissue levels of NF-kB or IL-6, indicating that other pathways are involved in the pathobiology of oral mucositis induced by this chemotherapeutic agent. Further investigation is required to explain the oral mucosa toxicity caused by 5-FU, especially with respect to induction of apoptosis and inhibition of cell proliferation as mechanisms.<sup>32</sup>

On the other hand, on D+10, PBM stimulated NF-kB activation and promoted clinical improvement of oral lesions. To the best of our knowledge, the results of this study are the first to indicate that PBM is useful to prevent and treat oral mucositis by stimulating the NF-kB pathway. These aspects could be explained by the fact that PBM induces angiogenesis and cell proliferation and epithelial migration, and prevents apoptosis.<sup>13,14,16</sup> Moreover, NF-kB activation has been implicated in survival responses of epithelial cells and increased angiogenesis mechanisms that involve VEGF expression.<sup>33</sup> In addition, several studies have shown that high levels of NF-kB are involved in the healing process.<sup>34-39</sup>

Haas et al.<sup>36</sup> used human keratinocytes in a culture to characterize the NF-kB response to wound healing associated or not associated with HeNe laser therapy. The authors showed that the wound-healing process combined with laser therapy increased expression of NF-kB at the wound edges, suggesting that this gene plays an important role in normal cutaneous wound healing. Egan et al.<sup>37</sup> showed that NF-kB is enhanced during intestinal epithelial wound closure. Tang et al.<sup>38</sup> reported that the NF-kB gene is activated during the healing process in chicken tendons.

The mechanisms that lead PBM to activate NF-kB are not fully elucidated. One accepted explanation is that PBM activates the NF-kB pathway via generation of mitochondrial ROS (mROS), which are produced via activation of a mitochondrial sensor of oxidative stress, protein kinase D (PKD).<sup>32,40</sup> PKD is then responsible for activation of the NF-kB signaling pathway via activation of IKK, a kinase that phosphorylates NF-kB inhibitors, resulting in degradation of the inhibitor, and release and nuclear translocation of NF-kB dimers.<sup>41,42</sup>

Our study emphasizes that PBM action in 5-FU-induced oral mucositis is modulated by NF-kB. We believe that these results help us to better understand the pathophysiological aspects of oral mucositis and the effect of PBM during inflammatory and tissue repair processes. The clinical benefits of PBM are well established; however, additional studies are needed to better understand the pathway by which NF-kB is activated by PBM, how this protein acts in the cell to enhance the wound healing process with different chemotherapy protocols, or how the levels of NF-kB could monitor and predict the oral



**Fig. 5** Western blot analysis of NF-κB protein level of each group according to experimental time (days 5, 10, and 15). Each blot represents a different animal (replicate). In the first line, we observed the protein expression in all groups on day 5; in the second line, we demonstrated it on day 10; and in the third line, on day 15. The control and therapeutic groups and the preventive and combined groups exhibited the same pattern of protein expression. In the control and therapeutic groups, the NF-κB level increased from day 5, peaked at day 10, and declined from days 10 to 15. In the preventive and combined groups, the NF-κB level decreased gradually from days 5 to 15. Different lower case letters indicate the statistical difference comparing each experimental group.

mucositis behavior. In future studies, it will be important to investigate the relationship between NF-κB levels and PBM in oral mucositis using NF-κB inhibitors associated with different chemotherapy and PBM protocols. One of our study limitations was that we observed the level of NF-κB in oral mucositis induced only by 5-FU; but it is well known that the type of drug administered could influence this protein. Other drugs in isolation or combined protocol need to be investigated.

In conclusion, in the animal model of oral mucositis used herein, PBM reduced the severity of mucositis by activating the NF-κB pathway, both when applied as a preventive modality and when given in a therapeutic protocol.

## References

- S. T. Sonis, "A biological approach to mucositis," *J. Supportive Oncol.* **2**(1), 21–32 (2004); discussion 35–26.
- S. T. Sonis, "Pathobiology of oral mucositis: novel insights and opportunities," *J. Supportive Oncol.* **5**(9 Suppl 4), 3–11 (2007).
- L. S. Elting et al., "The burdens of cancer therapy. Clinical and economic outcomes of chemotherapy-induced mucositis," *Cancer* **98**(7), 1531–1539 (2003).
- S. T. Sonis, "Oral mucositis," *Anti-Cancer Drugs* **22**(7), 607–612 (2011).
- R. M. Logan et al., "Serum levels of NFκappaB and pro-inflammatory cytokines following administration of mucotoxic drugs," *Cancer Biol. Ther.* **7**(7), 1139–1145 (2008).
- R. M. Logan et al., "The role of pro-inflammatory cytokines in cancer treatment-induced alimentary tract mucositis: pathobiology, animal models and cytotoxic drugs," *Cancer Treat. Rev.* **33**(5), 448–460 (2007).
- R. V. Lalla et al., "MASCC/ISOO clinical practice guidelines for the management of mucositis secondary to cancer therapy," *Cancer* **120**(10), 1453–1461 (2014).
- T. C. Lopez et al., "Effect of laser phototherapy in the prevention and treatment of chemo-induced mucositis in hamsters," *Braz. Oral Res.* **27**(4), 342–348 (2013).
- C. Scully, J. Epstein, and S. Sonis, "Oral mucositis: a challenging complication of radiotherapy, chemotherapy, and radiochemotherapy: part I, pathogenesis and prophylaxis of mucositis," *Head Neck* **25**(12), 1057–1070 (2003).
- C. Migliorati et al., "Systematic review of laser and other light therapy for the management of oral mucositis in cancer patients," *Supportive Care Cancer* **21**(1), 333–341 (2013).
- M. M. Schubert et al., "A phase III randomized double-blind placebo-controlled clinical trial to determine the efficacy of low level laser therapy for the prevention of oral mucositis in patients undergoing hematopoietic cell transplantation," *Supportive Care Cancer* **15**(10), 1145–1154 (2007).
- F. P. Eduardo et al., "Severity of oral mucositis in patients undergoing hematopoietic cell transplantation and an oral laser phototherapy protocol: a survey of 30 patients," *Photomed. Laser Surg.* **27**(1), 137–144 (2009).
- A. C. Pelliccioli et al., "Laser phototherapy accelerates oral keratinocyte migration through the modulation of the mammalian target of rapamycin signaling pathway," *J. Biomed. Opt.* **19**(2), 028002 (2014).
- V. P. Wagner et al., "Influence of different energy densities of laser phototherapy on oral wound healing," *J. Biomed. Opt.* **18**(12), 128002 (2013).

15. C. S. Dillenburg et al., "Efficacy of laser phototherapy in comparison to topical clobetasol for the treatment of oral lichen planus: a randomized controlled trial," *J. Biomed. Opt.* **19**(6), 068002 (2014).
16. M. M. Marques et al., "Effect of low-power laser irradiation on protein synthesis and ultrastructure of human gingival fibroblasts," *Lasers Surg. Med.* **34**(3), 260–265 (2004).
17. N. A. Pereira et al., "Effect of low-power laser irradiation on cell growth and procollagen synthesis of cultured fibroblasts," *Lasers Surg. Med.* **31**, 263–267 (2002).
18. C. M. Franca et al., "Low-intensity red laser on the prevention and treatment of induced-oral mucositis in hamsters," *J. Photochem. Photobiol., B* **94**(1), 25–31 (2009).
19. M. Curra et al., "Effect of topical chamomile on immunohistochemical levels of IL-1 $\beta$  and TNF- $\alpha$  in 5-fluorouracil-induced oral mucositis in hamsters," *Cancer Chemother. Pharmacol.* **71**(2), 293–299 (2013).
20. V. Lima et al., "Effects of the tumour necrosis factor- $\alpha$  inhibitors pentoxifylline and thalidomide in short-term experimental oral mucositis in hamsters," *Eur. J. Oral Sci.* **113**(3), 210–217 (2005).
21. F. M. de Lima et al., "Low-level laser therapy attenuates the myeloperoxidase activity and inflammatory mediator generation in lung inflammation induced by gut ischemia and reperfusion: a dose-response study," *J. Lasers Med. Sci.* **5**(2), 63–70 (2014).
22. Y. L. Hsieh et al., "The fluence effects of low-level laser therapy on inflammation, fibroblast-like synoviocytes, and synovial apoptosis in rats with adjuvant-induced arthritis," *Photomed. Laser Surg.* **32**(12), 669–677 (2014).
23. M. T. Manchini et al., "Amelioration of cardiac function and activation of anti-inflammatory vasoactive peptides expression in the rat myocardium by low level laser therapy," *PLoS One* **9**(7), e101270 (2014).
24. S. T. Sonis et al., "An animal model for mucositis induced by cancer chemotherapy," *Oral Surg. Oral Med. Oral Pathol.* **69**(4), 437–443 (1990).
25. R. F. Leitao et al., "Role of nitric oxide on pathogenesis of 5-fluorouracil induced experimental oral mucositis in hamster," *Cancer Chemother. Pharmacol.* **59**(5), 603–612 (2007).
26. J. H. Leborgne et al., "Corticosteroids and radiation mucositis in head and neck cancer. A double-blind placebo-controlled randomized trial," *Radiother. Oncol.* **47**(2), 145–148 (1998).
27. D. A. Hawkins and H. Abrahamse, "Phototherapy—a treatment modality for wound healing and pain relief," *Afr. J. Biomed. Res.* **10**, 99–109 (2007).
28. M. S. Moreira et al., "Effect of phototherapy with low intensity laser on local and systemic immunomodulation following focal brain damage in rat," *J. Photochem. Photobiol., B* **97**(3), 145–151 (2009).
29. L. Almeida-Lopes et al., "Comparison of the low level laser therapy effects on cultured human gingival fibroblasts proliferation using different irradiance and same fluence," *Lasers Surg. Med.* **29**(2), 179–184 (2001).
30. D. S. Basseres and A. S. Baldwin, "Nuclear factor- $\kappa$ B and inhibitor of  $\kappa$ B kinase pathways in oncogenic initiation and progression," *Oncogene* **25**(51), 6817–6830 (2006).
31. C. E. Badr et al., "Real-time monitoring of nuclear factor  $\kappa$ B activity in cultured cells and in animal models," *Mol. Imaging* **8**(5), 278–290 (2009).
32. S. Yamaoka et al., "Complementation cloning of NEMO, a component of the I $\kappa$ B kinase complex essential for NF- $\kappa$ B activation," *Cell* **93**(7), 1231–1240 (1998).
33. I. Elisia and D. D. Kitts, "Modulation of NF- $\kappa$ B and Nrf2 control of inflammatory responses in FHS 74 Int cell line is tocopherol isoform-specific," *Am. J. Physiol.: Gastrointest. Liver Physiol.* **305**(12), G940–G949 (2013).
34. K. Aota et al., "5-Fluorouracil induces apoptosis through the suppression of NF- $\kappa$ B activity in human salivary gland cancer cells," *Biochem. Biophys. Res. Commun.* **273**(3), 1168–1174 (2000).
35. S. Stifter, "The role of nuclear factor  $\kappa$ B on angiogenesis regulation through monocyte chemotactic protein-1 in myeloma," *Med. Hypotheses* **66**(2), 384–386 (2006).
36. A. F. Haas et al., "Redox regulation of wound healing? NF- $\kappa$ B activation in cultured human keratinocytes upon wounding and the effect of low energy HeNe irradiation," *Free Radical Biol. Med.* **25**(9), 998–1005 (1998).
37. L. J. Egan et al., "Nuclear factor- $\kappa$ B activation promotes restitution of wounded intestinal epithelial monolayers," *Am. J. Physiol.: Cell Physiol.* **285**(5), C1028–C1035 (2003).
38. J. B. Tang et al., "Expression of genes for collagen production and NF- $\kappa$ B gene activation of in vivo healing flexor tendons," *J. Hand Surg.* **29**(4), 564–570 (2004).
39. M. Li et al., "An essential role of the NF- $\kappa$ B/Toll-like receptor pathway in induction of inflammatory and tissue-repair gene expression by necrotic cells," *J. Immunol.* **166**(12), 7128–7135 (2001).
40. P. Storz, "Mitochondrial ROS—radical detoxification, mediated by protein kinase D," *Trends Cell Biol.* **17**(1), 13–18 (2007).
41. A. C. Chen et al., "Low-level laser therapy activates NF- $\kappa$ B via generation of reactive oxygen species in mouse embryonic fibroblasts," *PLoS One* **6**(7), e22453 (2011).
42. P. Storz, H. Doppler, and A. Toker, "Protein kinase D mediates mitochondrion-to-nucleus signaling and detoxification from mitochondrial reactive oxygen species," *Mol. Cell. Biol.* **25**(19), 8520–8530 (2005).

**Marina Curra** is a DDS, PhD student of the Department of Oral Pathology, School of Dentistry, Federal University of Rio Grande do Sul in Brazil. Her personal research interests are the clinical and basic aspects of oral mucositis. She had undergraduate research experience in oral pathology at the same university.

**Ana Carolina Amorim Pellicoli** is a DDS, MSc, PhD student of the graduation program of estomatopathology, School of Dentistry, State University of Campinas. She has a master's degree in oral pathology from the Universidade Federal do Rio Grande do Sul. She is a dentist with the School of Dentistry, Federal University of Rio Grande do Sul.

**Nélson Alexandre Kretzmann Filho** graduated in biological sciences from the Lutheran University of Brazil, MSc in genetics and applied toxicology from the same university, PhD in medicine from the Federal University of Health Sciences of Porto Alegre, and postdoc in pathology at Federal University of Health Sciences of Porto Alegre. He is currently professor of the Center University Ritter dos Reis-Laureate International Universities. He has experience in physiology and molecular biology, with emphasis on gastroenterology.

**Gustavo Ochs** graduated in biomedical sciences by the Federal University of Health Sciences of Porto Alegre. He is a MSc student in the Department of Genetics Therapies in Hospital de Clínicas de Porto Alegre.

**Úrsula Matte** graduated in biological sciences from the Federal University of Rio Grande do Sul in Brazil, and received her master's and PhD degree in genetics and molecular biology from Federal University of Rio Grande do Sul. She is currently associate professor of the Genetics Department of the Federal University of Rio Grande do Sul and develops its research activities in the Experimental Research Center of the Hospital de Clínicas de Porto Alegre. She is member affiliate of the Brazilian Academy of Sciences.

**Manoel Sant'Ana Filho** is a DDS in the School of Dentistry, Federal University of Rio Grande do Sul in Brazil. He received his MSc in oral and maxillofacial surgery and PhD in stomatology from the Pontifical Catholic University of Rio Grande do Sul. Currently, he is full professor in the Oral Pathology Department, School of Dentistry, Federal University of Rio Grande do Sul in Brazil.

**Marco Antonio Trevizani Martins** is a DDS of Paulista University, a resident in oncology dentistry with training in oral and maxillofacial surgery in the Stomatology Department of Cancer Hospital of São Paulo. He received his PhD in oral diagnosis from the School of Dentistry of São Paulo University. He is a postdoc at the University of Michigan and full professor in the Oral Pathology Department, School of Dentistry, Federal University of Rio Grande do Sul in Brazil. He develops activities in the stomatology Department of Hospital de Clínicas de Porto Alegre.

**Manoela Domingues Martins**, DDS, PhD, is a full professor in the Oral Pathology Department, School of Dentistry, Federal University of Rio Grande do Sul in Brazil. She is postdoc at the University of Michigan. Her personal research interests are the clinical and basic aspects of laser phototherapy in oral lesions and tissue regeneration.